

## CASE REPORT: AESTHETIC CHANGE OF ANTERIOR SIX UNITS

<sup>1</sup>Dr. Ana Gupta , <sup>2</sup>Dr. Ananya Sharma, <sup>3</sup>Dr. Rohit Kochhar

<sup>1</sup>, (Senior lecturer, IDS Sehora, Jammu India 180004)

<sup>2</sup>, (Senior lecturer, ITS Dental College, Greater Noida India 201310)

<sup>3</sup>, (HOD ITS Dental College, Greater Noida India 201310)

---

**ABSTRACT:** One of the major concern in maintaining the esthetic of the patient is the smile. Teeth is the important factor in a perfect smile. New treatment materials and methods have been discovered and introduced in market in order to gain this aim. Direct and Indirect Veneers restoration are the new restorative and esthetic approach. Direct Veneers are based on the principle of application of composite material directly on the prepared tooth surface and Indirect veneer are based on the laboratory production using composite or ceramic material and are cemented to the tooth surface with a adhesive material. In this case report veneers are made of ceramics using indirect method of fabrication.

---

### I. INTRODUCTION

Anterior teeth with esthetic treatment is always challenging in the clinical practice. Dentists must provide the best alternative and patients must choose the best alternative to improve oral condition and esthetic results in these circumstances. Many restorative options such as resin composites, all ceramic crowns, and ceramic veneers became available with the improvement of dental materials.<sup>[1]</sup> With the ever-increasing cosmetic demands of patients, it is essential to fully use all the tools available to dental care professionals.<sup>[2]</sup> ‘Smile Lift’ has been referred to Preparing all teeth in a visible smile. This is because other face features, including lips, can be enhanced with the use of supporting porcelain akin to a facial lift. Minimal intervention and still with good long term prognosis can be achieved by such changes.<sup>[3]</sup> In Cases with anterior dental wear and enough remaining sound dental structure Ceramic Laminate veneers are indicated. Ceramics color consistency, biocompatibility, mechanical properties, and esthetic outcome are the reasons for these treatment options.<sup>[2]</sup> The idea of minimally invasive dental restorations is essential for successful restorations.<sup>[4,5]</sup> Thus, minimum thickness ceramic laminate veneers have been increasingly indicated.

Indications for anterior veneer units

1. Diastemas and/or inappropriate incisal embrasure form.<sup>[6]</sup>
2. Chipping or wear limited to the front teeth.
3. Multiple black triangle disease .
4. Tooth position, either in standing, protruded or rotated. Sometimes even orthodontics alone cannot completely correct an occlusion and/or aesthetics unless an osteotomy is carried out.
5. Size shape discrepancies that are not correctable via orthodontics alone .
6. Poor colour or surface texture issues in an otherwise healthy dentition

### II. CASE REPORT

A Young patient aged 28yrs reported with the chief complain of discolored tooth and space between teeth in upper and lower tooth region since 10 years. Clinically Generalized flourosis with generalized diastema was observed (Fig-1). Diagnostic casts and waxed up restorations (Fig-2) were done to define shape and form to assist the treatment planning. Ceramic laminate veneers were indicated for the four maxillary incisors and two maxillary canines after evaluation of the casts.

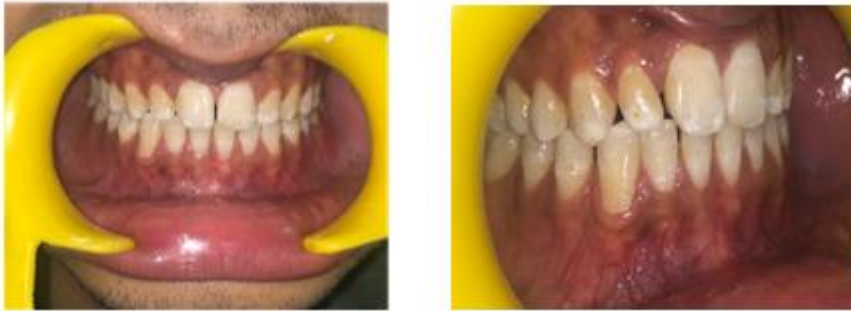

Fig-1:Preoperative Clinical pictures

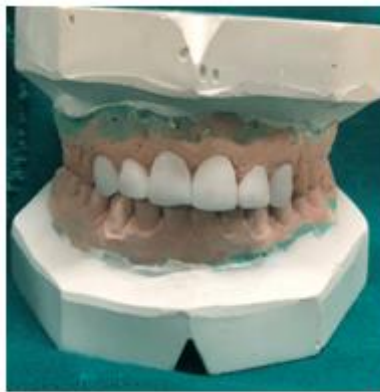
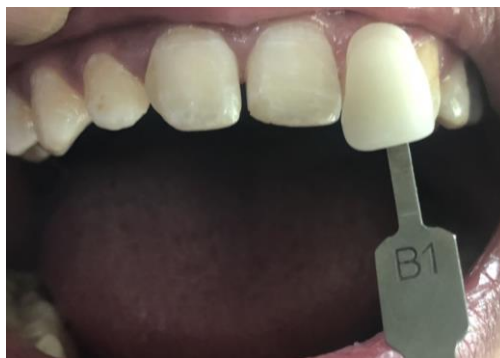
Fig-2: Waxed up restorations

Also Shade Selection was done in natural daylight in an afternoon. Shade selected was B1.



Tooth preparation was done using 3wheeled diamond bur. Tooth preparation done was minimal.(Fig-4)

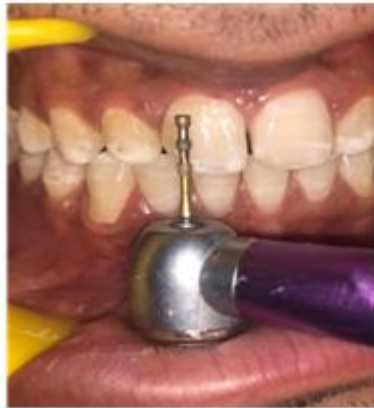

Fig-4: Veneer preparation using wheeled diamond bur

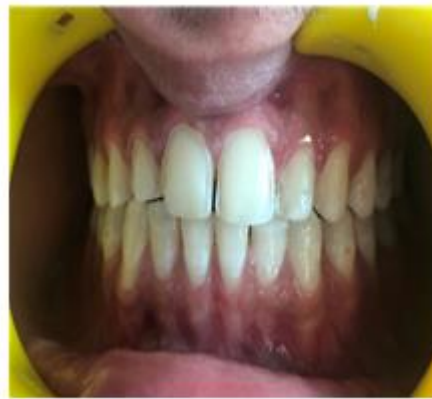

Fig-5: Post veneer preparation picture

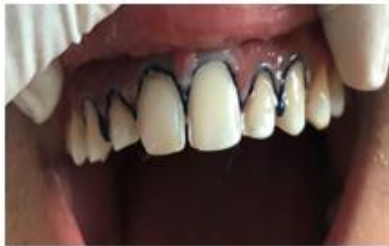

Fig-6: Retraction cord placement before

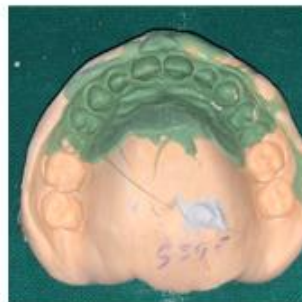


Fig-7: Polyvinyl impression of veneer

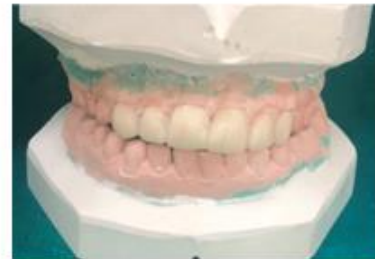

Fig-8: Provisional restoration

Retraction cord dipped in local anesthetic solution was placed to provide gingival sulcus enlargement (Fig-6) and impression was taken. The impressions were taken using a vinyl polysiloxane material (Fig-7) (Express XT, 3M ESPE, Seefeld, Germany). The trays were loaded with the heavy-bodied impression material, while the light-bodied impression materials were simultaneously spread on the teeth. Temporary Veneers were fabricated and delivered (Fig-8). In this case lithium disilicate-reinforced glass ceramic material (IPS e.max Press, Ivoclar-Vivadent, Liechtenstein) was used to fabricate Ceramic laminate veneer, using the heat press technique. A layering ceramic (IPS e.max Ceram, Ivoclar-Vivadent) was further applied to improve the incisal edge optical properties and characteristics. The veneers' internal surfaces to be bonded were etched with hydrofluoric acid (Porcelain Etchant 10%, Angelus) for 20 seconds, washed under running water (Fig-9), dried with an air syringe, and primed. One coat of the bonding resin of SE Cure (Parkell) was applied and light-cured. During the cementation, veneers were cemented separately one-by-one by applying the same bonding resin on the tooth surface. The laminate veneer restoration was bonded with a light-curable resin-based luting agent (SE Cure Parkell). The cement was applied to the veneers that were gently seated with finger pressure (Fig-10). Excess cement was removed with an explorer and a microbrush. The light polymerization was performed with a LED-curing unit for 30 s from buccal, incisal, mesial, and distal aspects of each tooth. Restorations were checked for any occlusal interference. The final restorative phase was achieved by polishing the marginal areas with a silicone instrument (Fig-11)

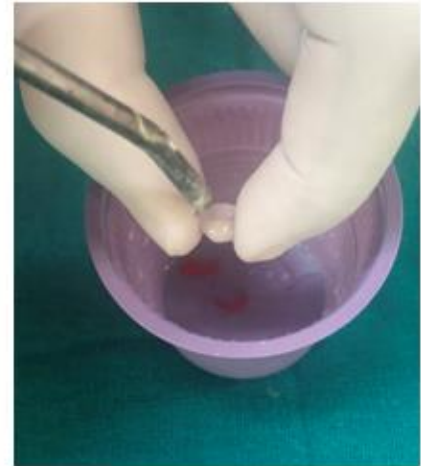
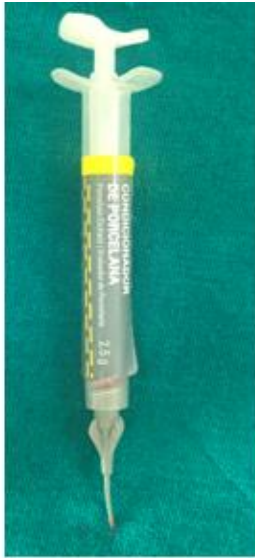
Fig-9: Surface treatment of intaglio surface of veneers

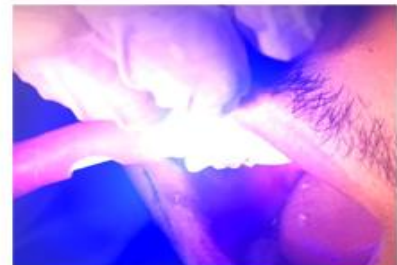
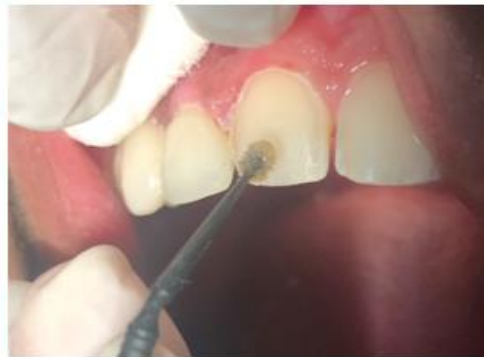
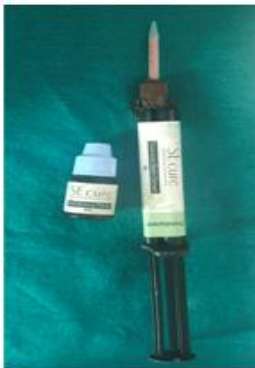Fig-10: Surface treatment of tooth surface of veneers and cementation

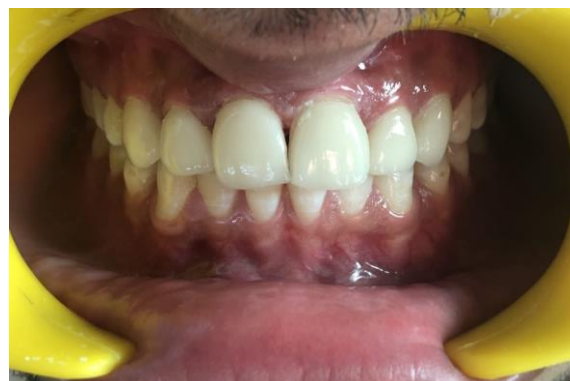

Fig10: Postoperative Clinical picture



### III. DISCUSSION

Diastema could be transient or created by developmental, pathological, or iatrogenic factors such as hypodontia, microdontia, mesiodens, abnormal oral habits, enlarge frenum, etc. The diagnosis of a diastema must be based on a thorough dental/medical history, clinical examination, and radiographic survey, Because of the potential for multiple etiologies. Removable orthodontic appliances, single arch, full arch or sectional fixed orthodontic appliances, excision of the frenum, restoration techniques, habit breaking appliances, extraction of mesiodens etc can be used as different treatment modalities. Diastema based on tooth-size discrepancy is most amenable to restorative and prosthodontic solutions. Even though orthodontic treatment is a viable option, most adults do not want to spend several years and multiple appointments to enhance their smiles. The restorative closure of diastema can be achieved by using any of the techniques mentioned; indirect composite veneers, direct composite veneers, porcelain laminate veneers, all ceramic crowns, metal ceramic crowns and composite crowns. Smaller diastema can be closed with microfilled and hybrid resins if the diastema is about 1–1.5 mm in dimension. Composite resin is easy to use, requires fewer appointments, is economic but offers less wear resistance and surface staining, which makes it inferior to dental porcelain<sup>[7]</sup>. Porcelain laminate veneers (PLVs) have become the alternative to composite restorations ceramic crowns and the traditional porcelain-fused-to-metal<sup>[8]</sup>. Smiles can be transformed painlessly, conservatively and quickly with dramatic, long-lasting results with the successful use of the porcelain laminate veneer. Tissue response is excellent, and the finished surface is very similar to the natural tooth. Veneers exhibit natural fluorescence and absorb, reflect, and transmit light exactly as does the natural tooth structure.

After being informed about advantages and disadvantages of each restorative option, the patient opted for the conservative ceramic veneers of minimum thickness. The long-lasting esthetics and little preparation of the underlying dental structure were among main reasons for this decision. Thus, in the presented clinical situation, the dental preparation was restricted to the enamel. Besides the optical characteristic similar to the dental structure, glass-ceramic materials have good bonding characteristics to the dental structure.<sup>[9]</sup> This increased retention is mainly related to the use hydrofluoric acid to etch their internal surfaces, associated with the use of silane-coupling agents.<sup>[10]</sup> Moreover, when the dental preparation is restricted to the enamel, improved and more reliable bonding may be obtained.<sup>[11]</sup>

### REFERENCES

1. Da Cunha LF, Reis R, Santana L, Romanini JC, Carvalho RM, Furuse AY. Ceramic veneers with minimum preparation. *Eur J Dent*. 2013;7(4):492-496. doi:10.4103/1305-7456.120645
2. Guess PC, Schultheis S, Bonfante EA, Coelho PG, Ferencz JL, Silva NR. All-ceramic systems: Laboratory and clinical performance. *Dent Clin North Am* 2011;55:333-52.
3. Dumfahrt H, Schaffer H. Porcelain laminate veneers. A retrospective evaluation after 1 to 10 years of service: Part II - Clinical results. *Int J Prosthodont* 2000; 13: 9-18.
4. Bloom DR, Padayachy JN. Aesthetic changes with four anterior units. *Br Dent J* 2006;200:135-8.
5. Radz GM. Minimum thickness anterior porcelain restorations. *Dent Clin North Am* 2011;55:353-70.
6. Gurel G. The science and art of porcelain laminate veneers. UK: Quintessence, 2003. 7. M. Viswambaran, S.M. Londhe, Vijaya Kumar, Conservative and esthetic management of diastema closure using porcelain laminate veneers. *Medical Journal Armed Forces India*, 2015;71:2.581-585
7. Touati B., Miara P., Nathanson D. Martin Dunitz; New York: 1999. *Esthetic Dentistry and Ceramic Restorations*; pp. 161–214.
8. Frese C., Staehle H.J., Wolff D. The assessment of dentofacial esthetics in restorative dentistry: a review of the literature. *J Am Dent Assoc*. 2012;143:461–466.
9. Calamia J.R., Simonsen R.J. Effect of coupling agents on bond strength of etched porcelain. *J Dent Res*. 1984;63:179.
10. Dar F., Atasu M. Macrodonia in association with a contrasting character microdonia. *J Clin Pediatr Dent*. 1999;23:271–274.